

**ORIGINAL ARTICLE:**

## Study on cardiac myxomas in high volume center

DR. SAMEER LAL\*, DR SATISH KUMAR, PROF DR SUBODH SATYARTHI, PROF DR M A GEELANI

DEPARTMENT OF CTVS, G. B. PANT INSTITUTE OF POSTGRADUATE MEDICAL EDUCATION AND RESEARCH (GIPMER),  
NEW DELHI, INDIA

CORRESPONDING AUTHOR\*

Corresponding author \*



This work is licensed under a Creative Commons Attribution-Non Commercial 4.0 International License

Date of Final acceptance: 30 Aug 2023

Date of Publication: 15 September 2023

Source of support: Nil

Conflict of interest: Nil

### Abstract:

Cardiac myxoma is the most frequent “benign” tumor of the heart which in itself is rare and can be malignant too and presents an important diagnostic challenge (4,43,47). Myxomas may resemble many cardiovascular or systemic diseases, and can arise in any of the cardiac chambers, although 75% occur in the left atrium. Most cases of atrial myxomas are now diagnosed in living patients, allowing successful surgical extirpation (1,3,30,44,53).

Before the introduction of angiocardiology in 1951, cardiac myxoma diagnosis was made only at autopsy (22). The first successful surgical removal of an atrial myxoma was performed in 1954 (35,47). In 1959, the first M-mode echocardiogram of a left atrial myxoma was reported (16). Indeed, the introduction of echocardiography has provided an important noninvasive means of diagnosis for cardiac myxomas (55). Thus, the diagnosis of small myxomas (less than 5 cm in size and asymptomatic) is becoming easier. We present a series of 10 patients operated in our institute (GIPMER) in the last 1 and half years the clinical symptoms ,diagnosis ,TEE findings before and after surgery post op follow up was assessed.

**Keywords:** cardiac myxoma , malignancy , cardiac chambers

### Introduction

Cardiac myxoma is the most frequent “benign” tumor of the heart which in itself is rare and can be malignant too and presents an important diagnostic challenge (4,43,47). Myxomas may resemble many cardiovascular or systemic diseases, and can arise in any of the cardiac chambers, although 75% occur in the left atrium. Most cases of atrial myxomas are now diagnosed in living patients, allowing successful surgical extirpation (1,3,30,44,53). Before the introduction of angiocardiology in 1951, cardiac myxoma diagnosis was made only at autopsy (22). The first successful surgical removal of an atrial myxoma was performed in 1954 (35,47). In 1959, the first M-mode echocardiogram of a left atrial myxoma was reported (16). Indeed, the introduction of echocardiography has provided an important noninvasive means of diagnosis for cardiac myxomas (55). Thus, the diagnosis of small

myxomas (less than 5 cm in size and asymptomatic) is becoming easier. We present a series of 10 patients operated in our institute (GIPMER) in the last 1 and half years the clinical symptoms ,diagnosis ,TEE findings before and after surgery post op follow up was assessed.

**AIM :** to study clinical features , operative findings , and post Operative features in cardiac myxomas . This is a retrospective non-experimental study. The study consists of 10 male and female patients, who underwent cardiac surgery with cardiopulmonary bypass (CPB) and myxoma excision. They were admitted in the ctvs department of a tertiary hospital in new delhi (gipmer) during January 2021 to December 2022. Regarding the left atrial myxomas, a transseptal approach with surgical excision was performed. Myxomas that developed right onto the atrial septum, were removed with a wide excision of the septum. As far as right atrial myxomas are concerned, an incision of the right atrium followed by excision of the myxoma along with excision of the atrial septum where needed, was performed.

**Materials and methods:**

10 consecutive patients of myxoma irrespective of type and with no exclusions were taken and clinical features assessed intra op findings and post op findings assessed and follow up for 6 months to 1 and half years done. None of the patients had recurrence till last follow up and did not have any familial history

All patients had consented for the study

**Statistical analysis**

The statistical analysis was performed with SPSS version 22.0. Analysis of independent variables such as sex, age, recurrence of the disease, specific site of myxoma development, cardiopulmonary bypass time, ischemia bypass time, use of intra-aortic balloon pump, Intensive Care Unit (ICU) length of stay, in-hospital length of stay and survival was conducted.

**Results**

Demographics

Table 1 Demographic and Intraoperative Data of Patients

	<i>n</i>	%
Sex		
Men	5	50
Women	5	50
Age, mean value (SD)	56,9 (14.1)	
Redo	0	
Operation type		
LA + RV Myxoma – excision	1	10
LA Myxoma – excision	6	60
LV Myxoma – excision	1	10
RA myxoma – excision	2	20

Ischemia time, mean value (SD) median value (Interq range)	40,0 (21,3)	37 (28-45)
CPB time, mean value (SD) median value (Interq range)	68,5 (30,2)	63 (51-78)

ICU STAY : IN ICU stay in the hospital depicted in table 2

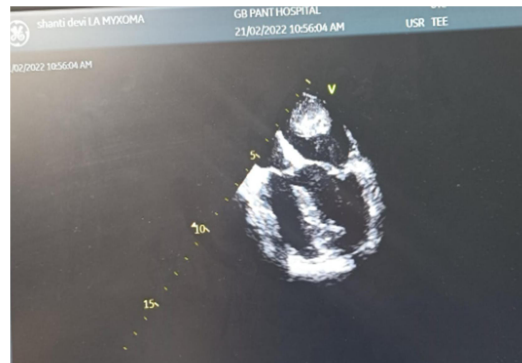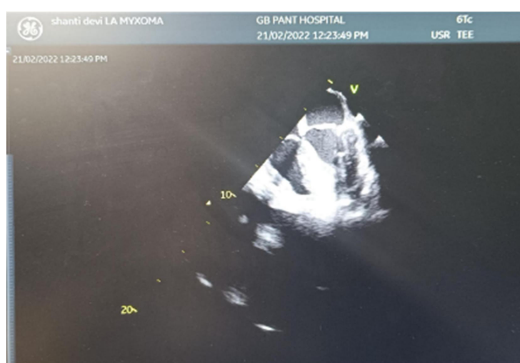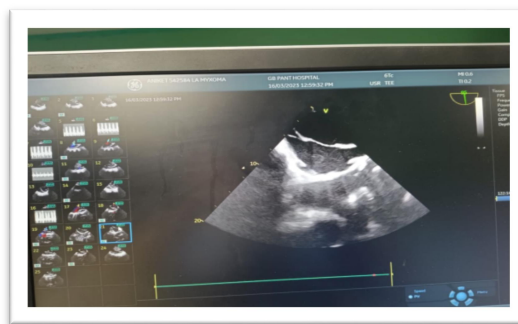
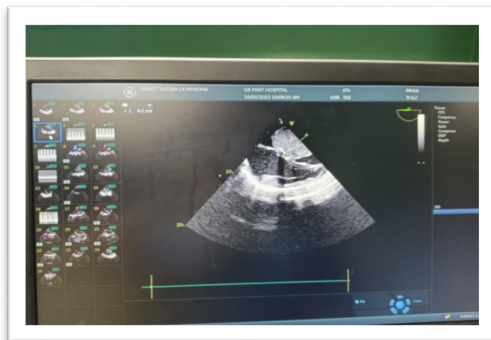In-hospital and ICU length of stay and survival outcome are demonstrated on [Table 2](#)

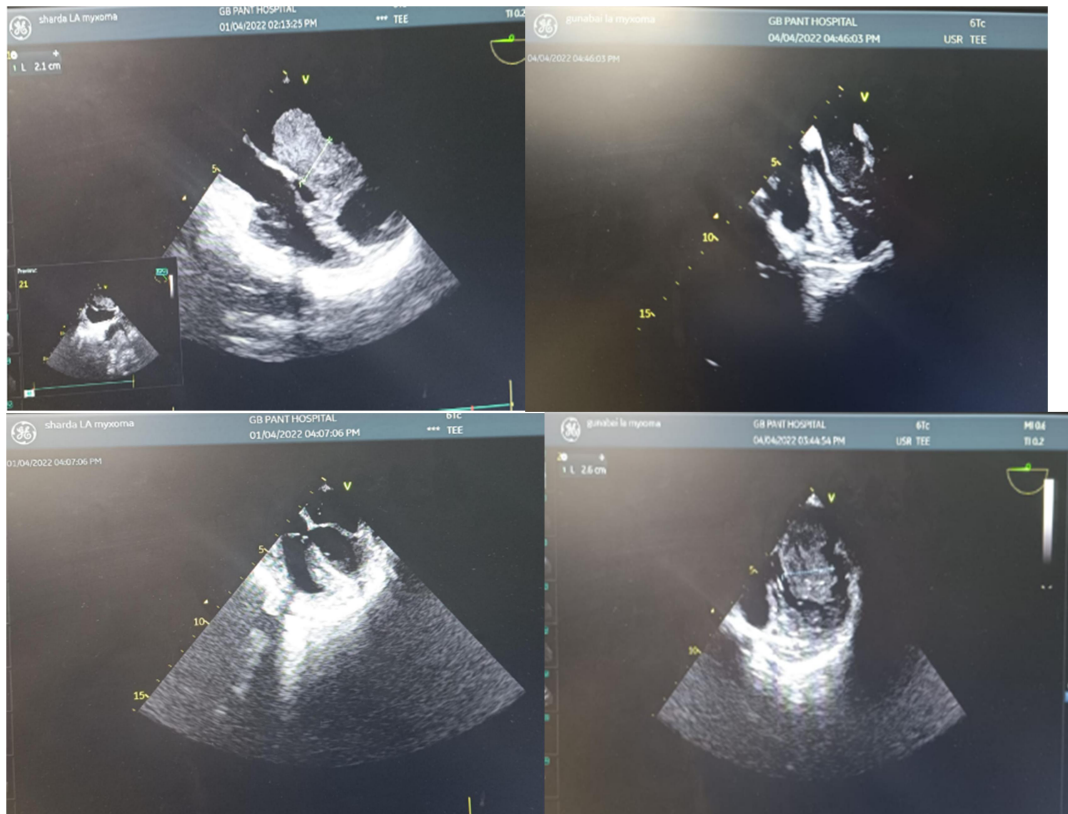
**Table 2** In-Hospital and ICU Length of Stay and Survival Outcome

	Range	Mean Value (SD)	Median Value (Interq range)
ICU length of stay	1-3	3 (11)	2 (1-2)
In-hospital length of stay	2-15	6,0 (2,1)	6 (4,5-7,0)
Survival outcome, <i>n</i> (%)			
Discharge		10 (100)	

Mean hospital stay was 6 days and all patients were discharged with one patient developed post op seizures

Some pre op and post op TEE findings figures 1 to 8





### Clinical features

Fever was the most common symptom 7 of the 10 of them had fever as constitutional symptom most of whom needed multiple admissions but none of them were evaluated for cardiac disease. loss weight and appetite was found in 5 of them .1 patient had syncopal episodes though ct and mri revealed no embolic phenomenon had a large RA myxoma. no patient was in failure and 3 patients had orthopnea especially those in RA myxoma and one with both ra lv myxoma . none of the patients had embolic phenomenon as were taken up on priority basis .generalized malaise was seen in all the patients .all of them had plop on auscultation one patient was found to severe Triuspid regurgitation which decreased to mild tricuspid regurgitation after surgery. None of them had familial history .dyspnea was seen in 6 patients ,only one patient had palpitation .

### Discussion

Cardiac myxomas are rare disease which represents 0.25% of all cardiac diseases.[14] The incidence per year doesn't exceed 0,5 to 1 case per million of subjects.[2] In our research, the demographic and intraoperative data of 10 patients who had undergone surgical excision of cardiac myxoma during the period 2001 to 2022 were analyzed statistically. We documented that intraoperative mean ischemia time was 40 minutes and mean CPB time was 68.5 minutes. We noticed a substantial difference from Gür's and Aykaç's[15] study surgical time. In their study, ischemia time was 23.6 minutes and CPB time was 35.4 minutes on a study population of 23 cases. Left atrium was the most common site of tumor growth (7of 10 cases, 70 %) and there was no difference between male to female sex in the study population. More specifically, 60% of patients were mean age was 57,9 years. no patients presented with recurrence of tumor , having the myxoma located at the left atrium mainly. 100 % of all patients fully

recovered. Our findings were not in accordance with Keeling et al.,[2] who investigated a series of 49 patients at Karl Franzens University, Austria. They observed a female predominance with sex ratio of 3:1 but however we found mostly middle-aged patients were affected in accordance with their study. In addition, Shah IK, et al.,[17] conducted a 50-year epidemiological screening of 194 patients at Cardiac Surgical and Biostatistical Department of Mayo Clinic, Rochester, Minnesota. Their results revealed that the left atrium was the most common site of tumor growth and the younger age of patients was related to tumor recurrence .but we did not find any recurrence Furthermore, in a study conducted by Bordalo et al.,[18] it was documented that an easier access to u/s scanning might provide a safer diagnose in a timely manner as 48% of patients were found to be asymptomatic. Similar to our study, Pérez-Andreu et al.,[19] also documented that an improvement in cardiac imaging techniques and a better accessibility to echocardiography revealed an increase of cases in the last three 5-year periods of their 24-year study (1990-2014). In our study, ALL of cases were incidental findings during a WORK UP for pyrexia of unknown origin in a primary healthcare facility.and most of the wer found to be from rural background .

### Conclusion

Fever and generalized malise was see in most of the patients .3 of them had orthopnea . Similar to Shah's study, the survival outcome post excision was very good ours showed a 100% survival till last follow up without recurrence . In conclusion, cardiac myxomas are uncommon but benign tumors. An easier access of the population to advanced cardiac imaging techniques on primary healthcare service facilities might provide earlier detection and diagnosis. Moreover, an improvement in perioperative management with a slight increase in perioperative surgical times has led to minimizing the in-hospital length of stay. Effective postoperative care and nursing management as an efficient means of hospital care may reduce the in-hospital length of stay as it was documented in our study. Instead of an epilogue, we could say that a surgical excision with an early adequate diagnostic management upon detection of the tumor can produce a very good survival outcome for patients.

### REFERENCES

1. Goldberg HP, Glenn F, Dotter CT, Steinberg I. Myxoma of the left atrium; diagnosis made during life with operative and post-mortem findings. *Circulation*. 1952;6:762–7.
2. Keeling IM, Oberwalder P, Anelli-Monti M, Schuchlenz H, Demel U, Tilz GP, et al. Cardiac myxomas: 24 years of experience in 49 patients. *Eur J Cardiothorac Surg*. 2002;22:971–7.
3. Reynen K. Cardiac myxomas. *N Engl J Med*. 1995;333:1610–7.
4. Bertherat J. Carney complex (CNC) *Orphanet J Rare Dis*. 2006;1:21.
5. Stratakis C. Mutations of the gene encoding the protein kinase A type I- $\alpha$  regulatory subunit (PRKAR1A) in patients with the “Complex of spotty skin pigmentation, myxomas, endocrine overactivity, and schwannomas” (Carney complex) *Ann N Y Acad Sci*. 2002;968:3–21.
6. Lazaros G, Masoura C, Brili S, Stavropoulos G, Kafiri G, Stefanadis C. Large left atrial myxoma in an oligosymptomatic young woman. *Hellenic J Cardiol*. 2013;54:60–3.
7. Li H, Guo H, Xiong H, Xu J, Wang W, Hu S. Clinical features and surgical results of right atrial myxoma. *J Card Surg*. 2016;31:15–7.

8. Stiver K, Bittenbender P, Whitson B, Bush C. Left atrial myxoma causing coronary steal: An atypical cause of angina. *Tex Heart Inst J*. 2015;42:270–2.
9. Goswami KC, Shrivastava S, Bahl VK, Saxena A, Manchanda SC, Wasir HS. Cardiac myxomas: Clinical and echocardiographic profile. *Int J Cardiol*. 1998;63:251–9.
10. Vilela EP, Moura L, Pepe D, Nunes E, Erthal F, Campana E. Giant atrial myxoma mimicking severe mitral stenosis in young patient. *Arq Bras Cardiol*. 2010;95:e125–7.
11. Zairi I, Mzoughi K, Jnifene Z, Fennira S, Moussa FB, Kammoun S, et al. A giant right atrial myxoma with pulmonary arterial hypertension. *Pan Afr Med J*. 2015;21:96.
12. Surabhi SK, Fasseas P, Vandecker WA, Hanau CA, Wolf NM. Right atrial myxoma in a patient presenting with syncope. *Tex Heart Inst J*. 2001;28:228–9.
13. Ikeda A, Tsukada T, Konishi T, Matsuzaki K, Jikuya T, Hiramatsu Y. Right atrial myxoma with a large tumor embolus in the left pulmonary artery. *J Surg Case Rep*. 2014;2014:rju115.
14. Bakkali A, Sedrati M, Cheikhaoui Y, Kacemi RD, Maazouzi W. Myxomes cardiaques (à propos de 23 cas opérés) *Ann Cardiol Angeiol*. 2009;58:94–8.
15. Gür AK, Aykaç MC. Surgical treatment of cardiac myxomas: A 23-case experience. *Heart Surg Forum*. 2018;21:E370–4.
16. Roschkov S, Rebeyka D, Mah J, Urquhart G. The dangers of cardiac myxomas. *Prog Cardiovasc Nurs*. 2007;22:27–30.
17. Shah IK, Dearani JA, Daly RC, Suri RM, Park SJ, Joyce LD, et al. Cardiac myxomas: A 50-year experience with resection and analysis of risk factors for recurrence. *Ann Thorac Surg*. 2015;100:495–500.
18. Bordalo AD, Alves I, Nobre AL, Silva F, Lemos A, Serpa C, et al. New clinical aspects of cardiac myxomas: A clinical and pathological reappraisal. *Rev Port Cardiol*. 2012;31:567–75.
19. Pérez-Andreu J, Arribas Leal JM, Gervase G, Rivera-Caravaca JM, López SC, Marín F. Epidemiology of cardiac myxoma in a Spanish population. A 30-year surgical series. *Rev Esp Cardiol (Engl Ed)* 2019;72:685–6.