

## Case Report:

# Corneoscleral Patch graft in a case of Mooren's ulcer: Case report

\*Dr.Ruchi Shah, Dr,Swetambari Singh , Dr, Dipali Satani , Dr, Bharti Bharadwaj , Dr.Amit Patel

C.H.Nagri Eye Hospital, Smt.N.H.L.Municipal Medical College, Ahmedabad , Gujrat

\*Corresponding author: Dr.Ruchi Shaha ; Email : drruchi12@gmail.com

### Abstract:

Mooren's ulcer is a rare disorder of unknown etiology that is refractory to treatment. It can affect not just the cornea but also the scleral tissue and can involve both eyes. We report a case of a 25-year-old young male with a history of bilateral and malignant Mooren's ulcer. The patient had lost left eye to perforation of Mooren's ulcer before 3 years. The perforated Mooren's corneal ulcer also presented in the right eye and involved the adjacent scleral tissue. A crescent shaped corneal-scleral patch graft was performed to preserve the anatomical integrity of the eye as well as vision alongwith local as well as systemic immunosuppression. This report highlights how a corneal-scleral patch graft followed by systemic and local immunosuppressive treatment can be considered in monocular patients with malignant Mooren's ulcer which can prove to be globe saving as well as vision saving.

**Keywords:** Mooren's ulcer, patch graft

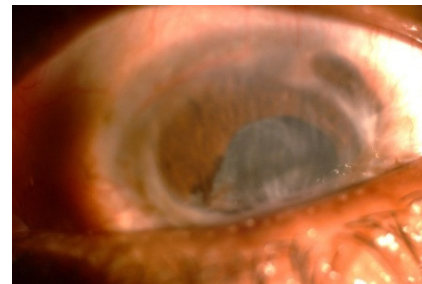
### Introduction:

Mooren's ulcer is a rare disorder presenting as chronic and painful ulceration of the cornea. The lesion with overhanging edges generally starts on the periphery and tends to spread progressively to the entire circumference or towards the centre of the cornea. As well as the cornea, the sclera can also be involved with an incidence of 13.5% of eye perforation and loss of vision [1]. We describe a case of crescent shaped patch grafting in a patient with Mooren's ulcer and corneoscleral perforation inferiorly.

### Case presentation:

A 25-year-old male presented at our clinic with a 2 day history of loss of vision in his right eye associated with redness, watering, pain and photophobia since 1 week. 3 years back he had an

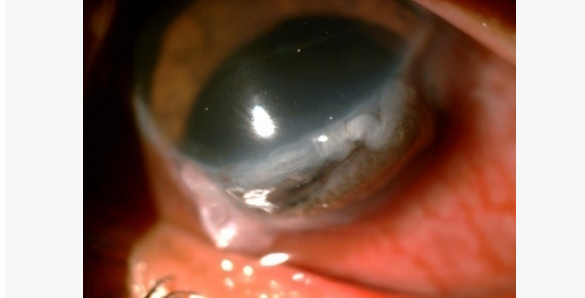
episode of similar symptoms in the left eye following which he lost left eye which had then become pthisical.



**Photograph 1: Pthisical left eye**

Medical examination of right eye revealed acute conjunctival hyperaemia and a large inferiorly perforated Mooren's ulcer extending almost from 3 to 8 o'clock hours. The anterior chamber was shallow with iris prolapse. Patient was aphakic with orange glow (probably patient had trivial trauma

superimposed on the existing condition leading to a large perforation with lens extrusion) (Photograph 1). Visual acuity was hand movements.

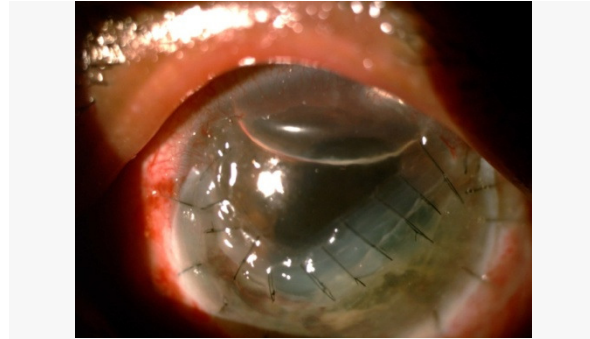


**Photograph 2. Perforated Mooren's ulcer.**

Under general anaesthesia, we performed an inferior crescent shaped corneoscleral patch graft. The surgical technique included conjunctival peritomy inferiorly to explore extent of perforation and involvement of sclera. The anterior chamber was formed with viscoelastics and prolapsed iris was repositioned. The involved cornea and scleral ring was removed. The recipient bed was measured and donor tissue prepared from a whole eye used within 24 hours of the donor's death and stored in a moist chamber using free hand dissection. Care was taken to scrape off the uveal tissue from the donor tissue. The donor corneoscleral graft was then sutured into place onto the scleral edge using 8.0 interrupted silk sutures and corneal edge using 10.0 interrupted ethilon sutures. The anterior chamber was washed with balanced salt solution (BSS) and filled with air. Patient was kept aphakic. The conjunctiva was closed with Vicryl 8.0 interrupted sutures.

The day after surgery we found a mild keratitis with a low flare in the anterior chamber. Postoperative steroid therapy was prednisolone acetate 1% every two hours for four weeks (decreased to four times a day for five months), oral cyclosporine A (5

mg/kg/day) for six months and prednisone (started at 2 mg/kg/day tapered gradually over 12 months). After six months the best corrected visual acuity was 6/60.



**Photograph 3. Corneoscleral patch graft after 3 days.**

#### **Conclusion and Discussion:**

The presented case was a malignant form of bilateral Mooren's ulcer that had already caused a corneal perforation in the left eye with consequent phthisis bulbi. Patient presented with similar perforation in the right eye and so a corneoscleral graft was necessary. The etiopathogenesis of Mooren's ulcer is still unknown. It is probably an autoimmune disease. Indeed, anti-corneal and anti-conjunctival tissue antibodies have been isolated from patients suffering from this disorder [2]. Furthermore, the conjunctival tissue surrounding the lesion is generally rich in proteo-glycolytic enzymes secreted by mononucleate cells and neutrophils that progressively infiltrate the area surrounding the ulcer [3]. Another confirmation of the autoimmune origin of the disorder is the T-suppressor lymphocytes deficit in patient blood samples [4].

Wood and Kaufman classified Mooren's ulcer in two main forms [5]. Type 1 is the benign form, generally monolateral, which mainly affects the elderly. The

symptoms are unclear but this type responds well to medical and surgical management. Type 2 is the malignant form. It can occur bilaterally in 25% of cases in white subjects and 75% in black subjects. It mainly affects younger individuals. Watson divided the disease into three types based on the clinical presentation: unilateral Mooren's ulcer, bilateral aggressive Mooren's ulcer and bilateral indolent Mooren's ulcer [6].

In the third type of Watson and in the malignant form of Wood and Kaufmann, we have a progressive ulcer that affects not just the cornea but also the scleral tissue. For this reason, neither conventional medical nor surgical treatment is sufficient, and it can be necessary to perform a large corneoscleral graft to preserve the anatomical integrity of the eye.

Indeed, it is extremely difficult to treat Mooren's ulcer and in many cases, the results are poor. Treatment starts with cortisone administered systemically and locally, but if this is unsuccessful, the complete excision of the perilimbal conjunctiva and episclera near the ulcer is made [6]. The use of immunosuppressive drugs, in particular cyclosporin A, should be reserved for more severe forms [7]. In the event of small corneal perforation, the area can be covered with amniotic membrane or a lamellar keratoplasty can be performed [8]. In this case, because of the presence of a large, perforated corneal ulcer affecting the scleral tissue and the patient being one eyed, it was decided to perform a corneoscleral patch graft.

The use of total corneoscleral grafts to treat serious corneal disorders was first proposed in the early 1970s [9]. The percentage of surviving graft tissue

has always been very low mainly because of the early onset of epithelial damage to the transplanted tissue, recurrence of the underlying disorder or secondary glaucoma caused by the disturbance of the iridocorneal angle and thereby of aqueous humour filtering [10]. In this case, the particular technique used made it possible to preserve the iridocorneal angle, and the administration of systemic and local cyclosporin treatment avoided the onset of secondary glaucoma as well as any sign of rejection six months after the operation. For this reason, we think that this type of graft can be proposed mainly for monocular patients with malignant Mooren's ulcer where there is high risk and where eyes would otherwise be condemned to a complete loss of vision.

#### References:

1. Jiaqi Chen, Hanping Xie, Zhen Wang, Bing Yang, Zuguo Liu, Longshan Chen, Xiangming Gong, Yuesheng Lin: Mooren's ulcer in China: a study of clinical characteristics and treatment. *Br J Ophthalmol* 2000, 84:1244-49.
2. Schaap OL, Feltkamp TEW, Breehart AC: Circulating antibodies to corneal tissue in a patient suffering from Mooren's ulcer (ulcus rodens corneae). *Clin Exp Immunol* 1969, 5:365-72.
3. Brown SL: Mooren's ulcer: histopathology and proteolytic enzymes of adjacent conjunctiva. *Br J Ophthalmol* 1975, 59:670-4.
4. Murray PI, Rahi AHS: Pathogenesis of Mooren's ulcer: some new concepts. *Br J Ophthalmol* 1984, 68:182-7
5. Wood TO, Kaufman HE: Mooren's ulcer. *Am J Ophthalmol* 1971, 71:417-22.

6. Watson PG: Management of Mooren's ulceration. *Eye* 1997, 11:349-56.
7. Hemady R, Tauber J, Foster CS: Immunosuppressive drugs in immune and inflammatory ocular disease. *Surv Ophthalmol* 1991, 35:369-85.
8. Nian ZD, et al.: Mooren's ulcer treated by lamellar keratoplasty. *jpn j ophthalmol* 1979, 15:290-4.
9. Ticho U, Ben-Sira I: Total keratoplasty. *Arch Ophthalmol* 1973, 90:104-6.
10. Cobo M, Ortiz JR, Safran SG: Sclerokeratoplasty with maintenance of the angle. *Am J Ophthalmol* 1992, 113:533-7.

Date of submission: 2 March 2013  
Date of Provisional acceptance: 17 March 2013  
Date of Final acceptance: 28 April 2013  
Date of Publication: 03 June 2013  
Source of Support: Nil ; Conflict of Interest: Nil