

Case Report

An undivided retro-mandibular vein receiving facial and posterior auricular vein:

Case report and clinical repercussion

* **Nidhi Gupta¹, Pooja Jain¹, Ashutosh Anshu², Samta³**

¹Department of Anatomy, All India Institute of Medical Sciences, New Delhi, India.

²Vardhman Mahavir Medical College and Safdarjang Hospital, New Delhi, India.

³Ganesh Shanker Vidyarthi Memorial Medical College, Kanpur, India.

***Correspondence:** Dr. Nidhi Gupta, Department of Anatomy

All India Institute of Medical Sciences, New Delhi, India.

E-mail: drnidhiiaims@gmail.com

ABSTRACT:

During routine superficial dissection on the left side of, certain striking variations were observed. The retromandibular vein measuring 3 cm remained undivided to continue as a single trunk. The facial vein did not course through the submandibular triangle; rather it was confined within face and retromandibular region. Moreover, instead of draining into internal jugular vein, it joined the undivided retromandibular vein at a distance of 3 cm antero-superiorly from the inferior angle of mandible, to form external jugular vein. Undivided retromandibular vein received another tributary as posterior auricular vein besides facial vein. Upon deeper dissection, no anastomotic channel was found between internal jugular and external jugular vein.

Literature is studded with anomalous venous pattern in head and neck region. Retromandibular vein through its two division channel the venous blood obtained from the face and scalp to internal and external jugular vein respectively. Such variations are attributed to altered vasculogenesis during embryonic life. Any alteration in its structure implies clinically significant outcome in planning procedures, as the territorial drainage are consequently distorted and often misinterpreted. The awareness of such variations is vital to anatomists, maxillofacial surgeons, radiologist and intensivist. All such medical personnel undertaking procedures in these regions should be cautious and prepared to encounter the possibility of anatomical alterations. A primary clinical screening followed by detailed radiological examination when in confusion, is highly suggestible to preclude hazards, failure and misinterpretation prior to any routine clinical assessment and intervention in this territory.

Keywords: external jugular vein: facial vein: retromandibular vein.

BACKGROUND

As the superficial veins of head and neck exhibits myriad of variations in their formation and distribution, the standard description consist of the relatively constant pattern of these venous arrangement most frequently observed (1). The usual venous architecture commences when the

supraorbital and supratrochlear vein unites to form angular vein near the medial canthus of eye in the anterior part of the face. The angular vein after its formation, courses obliquely backward and downward in the face, where it receives the superior labial vein to become superficial facial vein. Facial vein is finally derived after the

superficial facial vein had received tributaries from inferior labial, submental, deep facial and other small veins of face. Facial vein courses beneath the facial artery to reach the antero-inferior angle of masseter where it pierces the deep cervical fascia. After crossing the superficial lobe of submandibular gland in the digastrics triangle, it unites with the anterior division of retromandibular vein to form common facial vein, which finally empty into internal jugular vein.

On the posterior aspect of face, the maxillary vein draining the pterygoid area unites with superficial temporal vein to form the retromandibular vein within the substance of parotid gland. The retromandibular vein runs a very short distance behind the ramus of mandible before it divides into anterior and posterior division (1).

The posterior auricular vein draining the temporo-occipital region of the scalp descends behind the auricle to join the posterior division of retromandibular vein just below and behind the apex of parotid gland, to form external jugular vein (1).

The morphology, relative size, disposition, tributaries and termination of subcutaneous veins of head and neck region may exhibit enormous variations (2). The recognition of such anomalous patterns is imperative for anatomist, clinicians, anesthetists, surgeons, and radiologist.

The current case documents and discusses unusual termination of facial vein and posterior auricular vein into undivided retromandibular vein and its clinical insinuation.

CASE REPORT

Striking variations were observed during routine superficial dissection on left side of face in a 60 years old male embalmed cadaver at gross Anatomy laboratory, Department of Anatomy,

AIIMS, New Delhi. The superficial facial vein (SFV) traversed nearly horizontally from the angle of mouth and collected the blood from the deep facial vein (DFV) running in front of anterior border of parotid gland to form facial vein (FV) (Fig. 1). The FV almost immediately united with the undivided RMV at a distance of 3 cm antero-superiorly from the inferior angle of mandible, to form external jugular vein (EJV).

Upon deeper dissection, the RMV was seen to be normally formed by the joining of maxillary and superficial temporal veins, 1 cm antero-inferior to the tragus of the ear. The length of RMV was 3 cm. The RMV instead of bifurcating into anterior and posterior branches at the level of apex of parotid gland remained undivided. It received a tributary from posterior auricular vein (PAV).

An anonymous vein (AnV) drained into the commencing EJV, just distal to the point of union FV and RMV.

EJV when traced further distally in the roof of posterior triangle of neck, was seen receiving posterior external jugular vein (PEJV) at a distance of 3.5 cm postero-inferiorly from the inferior angle of mandible. Eventually after receiving transverse cervical vein (TCV) it pierced the deep fascia of the neck to join the subclavian vein 0.5cm above the midpoint of clavicle.

Common facial and the divisions of retromandibular veins were completely absent in the present case. Internal jugular vein was normal in morphology except that it did not receive any common facial vein. When meticulous dissection was done on the right side of the face no such aberrant findings were found. Any history of injury or incision inflicted on the face was not found in the record.

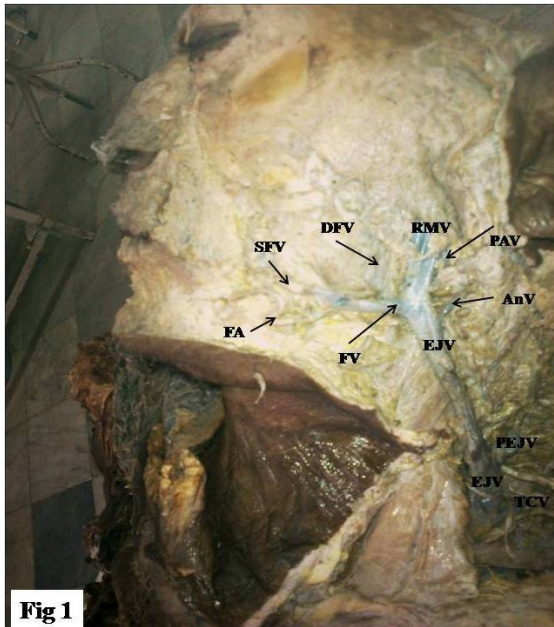


FIGURE LEGENDS:

- SFV = Superficial facial vein
- DFV = Deep facial vein
- FV = Facial vein
- RMV = Retromandibular vein
- FA = Facial artery
- PAV = Posterior auricular vein
- AnV = Anonymous vein
- EJV = External jugular vein
- PEJV = Posterior external jugular vein
- TCV = Transverse cervical vein.

DISCUSSION

There are evidences of failure of division of RMV into anterior and posterior branches (3, 4).

The incidence of undivided RMV was found to be 1 out of 104 specimens in one study (3), which is very much similar to our case but the degree of angulations of FV with the RMV was reasonably different. Moreover, an anonymous vein (AnV) draining into EJV just distal to its formation represents a unique scenario.

In another case (4), an undivided RMV had been seen joining only the PAV to form EJV, while the FV drained into the fenestrated IJV, which too stands in clear difference with our case.

The abundance of literature on venous variations in the head and neck region reveals erratic drainage of facial vein into constituent conduits, in the main trunk or in the divisions of RMV. The higher termination of facial vein into superficial temporal vein destined to end in normally ramifying RMV (5) or in the anomalous undivided RMV (6) had been seen in the past. Sometimes the FV instead of

draining into the anterior branch of RMV, can empty directly into the trunk of RMV at a higher level in the parotid gland (7). However, unlike RMV continuing as undivided trunk as in our case, it ramified into anterior and posterior division in that case. The drainage of facial vein into external jugular vein instead of internal jugular vein (5, 8) or into subclavian vein (9) is also documented.

In the present case the facial vein, rather than collecting blood from the anterior division of RMV directly integrated with the RMV to form EJV. Thus it appears as if the FV drains into external jugular vein. The FV had been described terminating in external jugular vein with varying degree of obliquity (10) in Y-shaped, U-shaped, tuning fork shaped, N-shaped, inverted A-shaped or a stepladder-shaped pattern which is in accordance with Y-shaped pattern observed in current case. In the present case, no anastomotic channel was found connecting EJV with IJV, which is otherwise present in one third cases (11). Additionally the remarkable failure of division of RMV leads to lack

of formation of common facial vein, which represents a situation in which the IJV is totally deprived of blood draining from anterior aspect of face and simultaneous acquisition of the drainage of this territory by EJV.

The possible explanation for such discrepancy is attributed to developmental defect in sequential retention and regression of primitive vessels during morphogenesis (12).

The ventral pharyngeal vein after receiving the blood from mandibular and hyoid arches becomes linguofacial vein (LFV). LFV anastomoses with primitive maxillary vein to form future anterior facial vein (AFV). During vasculogenesis RMV after its formation in the temporal region, divides into anterior and posterior division.

The anterior division of RMV joins the LFV to form common facial vein CFV. The CFV after its formation opens into the primitive precardinal vein PCV which forms the future IJV. EJV arising in the neck region connects anteriorly with LFV through an anastomotic channel and posterior division of RMV and posteriorly with PAV. The aforesaid mentioned anastomotic connection of RMV with the FV gradually disappears and the resultant union of PAV and the posterior division of RMV ultimately forms EJV.

In the current case as the RMV have failed to divide, as a result the LFV could not connect to the primitive PCV through CFV. Additionally, the anterior connection of EJV with the LFV was retained; therefore the FV appears to be directly connected to RMV, thus forming EJV.

The precise development pattern of the subcutaneous veins of head and neck region is not very clear (12), yet embryological correlation with variations in morphology of these vessels is highly

instructive to medical personnel working in these regions.

The age old practice of estimation of central venous pressure by inspection of neck veins in cardiac examination might mislead the clinicians in presence of venous variations. The engorged jugular veins may be the only clinically evident marker for superior vena cava syndrome (13). Furthermore, the variant venous architecture of face can perplex the intensivist while placing the cannula in external jugular veins for monitoring the central venous pressure and infusion of drugs and fluids in total parenteral nutrition. External jugular and common facial veins are frequently employed in ventriculojugular shunts (14). Recently permanent catheterization for hemodialysis is established using these superficial veins. Facial and external jugular veins are utilized as autogenous conduits for carotid angioplasty following carotid endarterectomy in cases of stenosis, by vascular surgeons. The rich communication of veins of head and neck favors deriving of grafts in plastic surgeries. The success of cutaneous platysma flaps and myocutaneous sternocleidomastoid flaps, which are being increasingly used in major cancer maxillofacial surgeries, depends upon meticulous microvascular anastomosis of vasculature in this region. The anomalous venous pattern in this region may result in failure to design effective grafts with optimum viability. The common facial vein drains into internal jugular vein at a point just above the bifurcation of common carotid artery, which serves as important landmark for exploring carotid sheath. The exposure of facial nerve in superficial parotidectomy and management of condylar fracture of mandible is guided by the course of retromandibular vein as these veins are quite vulnerable to injuries in submandibular excision to expose the mandible. External jugular vein is customarily used in transjugular liver biopsy and portosystemic shunts. The acquaintance of such variations facilitates avoiding misidentification and misinterpretation of veins of the neck

and face during contrast angiography. Caution must be exhibited in ligating these veins during en-bloc lymph nodes dissection of the neck to shun bleeding. Biocompatibility studies of synthetic prostheses prior to its in vivo application make use of these veins. Neglecting any disparity in underlying venous pattern predisposes to inadvertent excessive bleeding while attempting surgeries in this region. Any malformation, absence or altered disposition of the superficial veins of the head and neck and their tributaries must be considered beforehand while planning any invasive procedure. The preoperative evaluation of the draining pattern of venous networks of head and neck by precise clinical appraisal followed by doppler ultrasonographic studies are highly recommended to circumvent intraoperative 'trial and error' procedures during surgery (15). The anatomico-embryological understanding of formation, course, morphology, relative size, disposition, anastomosis, tributaries valves and variations of these veins is indispensable for surgeons to accomplish success in surgeries. The variations in the current case may be of particular interest to the anatomist and surgeons.

REFERENCES

- 1.Gray's Anatomy. 38th ed. Williams PL, Bannister LH, Berry LH, Collins P, Dyson M, Dussek JE, Fergusson MWJ, Churchill Livingstone Inc. New York.1995; 1576-1580.
- 2.Bertha A, Suganthi R. JCDR. 2011; 5(1):24-27.
- 3.Pai M, Vadgaonkar R, Prabhu L, Shetty P. The different termination patterns of the facial vein – a cadaveric study. *Firat tıp dergisi*. 2008; 13(1): 32-34.
- 4.Devi SK, Sharmila BP. IJAV. 2011; 4: 144–146.
- 5.Prakash R; Prabhu L V; Kumar J; Nayak V , Singh G. Variations of jugular veins: phylogenetic correlation and clinical implications. *South Med. J*. 2006; 99(10):1146-7.
- 6.Peucker ET, Fischer G, Filler TJ. Facial vein terminating in the superficial temporal vein: a case report. *J Anat*. 2001; 198: 509–510.
- 7.Kopuz C, Yavuz S, Cumhur M, Tetik S, Ilgi S. An unusual coursing of the facial vein. *Kaibogaku Zasshi*. 1995; 70: 20-22.
- 8.Choudhry R, Tuli A, Choudhry S. Facial vein terminating in external jugular vein. An embryological. *Surg Radiol Anat*. 1997; 19(2):73-7.
- 9.Prakash BB, Bhagath KP. A rare termination of left common facial vein into left subclavian vein: A case report. *Int J Morphol*. 2007; 25(3):555-6.
10. Gupta V, Tuli A, Choudhry R, Agarwal S, Mangal A. *Surg Radiol Anat*. 2003; 25(1):36-41.
11. Holinshed WH. *Anatomy for surgeons*. Vol 3, 3rd Ed. Jagerstown, Harper& Row. 1982; pp467.
12. Williams PL, Bannister LH, Berry LH, Collins P, Dyson M, Dussek JE, Fergusson MWJ. *Grays Anatomy*. 38th Ed. Churchill Livingstone Inc. New York 1995; pp326-327.
13. Baumgartner, I & Bollinger, A. Diagnostic importance of the jugular veins. *Vasa*. 1991; (20): 3-9.
14. Gogolev MP. The treatment of hydrocephalus by ventriculojugular shunting. *Zh. Vopr. Neurokhir. Im .N.N. Burdenko* 1993; Jul-Sept (3) 24-6.
15. Nagase T, Koboyashi S, Sekiya S, Ohmori K. Anatomical evaluation of the facial artery and vein using color doppler ultrasonography. *Ann Plast Surg*. 1997. 39: 64-67.

Date of submission: 07 February 2013
Date of Provisional acceptance: 12 March 2013
Date of Final acceptance: 28 April 2013
Date of Publication: 03 June 2013
Source of Support: Nil ; Conflict of Interest: Nil