

Case Report:

An Unusual Formation of the Femoral Nerve - A Case Report

¹Dr. Indrajit Gupta , ²Dr. Sudeshna Majumdar* , ³Dr. Santanu Bhattacharya , ⁴Dr. Seikh Ali Amam ,
⁵Dr. Susmita Ghosh , ⁶Dr. Lopamudra Mandal

¹Professor, Department of Anatomy, North Bengal Medical College, Darjeeling - 734432, West Bengal, India.

²Professor, Department of Anatomy, Nilratan Sircar Medical College, Kolkata – 700014, West Bengal, India.

³Assistant Professor, Department of Anatomy, Calcutta National Medical College, Kolkata-700014, West Bengal , India.

⁴Associate Professor, Department of Anatomy, Nilratan Sircar Medical College, Kolkata – 700014, West Bengal, India.

⁵Assistant Professor, Department of Anatomy, Calcutta National Medical College, Kolkata-700014, West Bengal, India.

⁶Assistant Professor, Department of Anatomy, Calcutta National Medical College, Kolkata-700014, West Bengal, India.

*Corresponding author: Dr. Sudeshna Majumdar : Mail: sudeshnamajumdar.2007 @ rediffmail.com

Abstract

The femoral nerve is derived from the lumbar plexus. The variations in the lumbar plexus and its branches have clinical importance. While doing the routine dissection in the Department of Anatomy, Calcutta National Medical College, Kolkata, India, a variation was found in the formation of the femoral nerve in a 60 year old male cadaver in the year 2011. In this case the femoral nerve was getting an extra twig from the lumbosacral trunk. Awareness of the possibility of encountering a variation like this may prevent postoperative complications. This case report will also enhance our knowledge in Anatomy.

Key Words: femoral nerve, Lumbar plexus, lumbosacral trunk.

Introduction

The lumbar plexus lies within the posterior part of the substance of the psoas major muscle. It is formed by the first three and most of the fourth lumbar ventral rami (L1 to L4) with a contribution from the 12th thoracic ventral ramus (T12). There may be minor variations in the formation of this plexus¹. The first lumbar ventral ramus, joined by a branch from the 12th thoracic ventral ramus, bifurcates and the upper and the larger part again divides into iliohypogastric and ilioinguinal nerves. The smaller lower part joins with a branch from the second lumbar ventral ramus to form the genitofemoral nerve. The remainder of the second to fourth lumbar ventral rami divide into ventral and dorsal branches – the ventral branches unite to form the obturator nerve while the dorsal branches divide into larger and smaller branches;

larger dorsal branches unite to form the femoral nerve and the smaller branches form the lateral femoral cutaneous nerve¹. The accessory obturator nerve, when it exists, arises from the third and fourth ventral branches¹ [Figure – 1].

The lumbar part of the lumbosacral trunk contains part of the fourth and all of the fifth lumbar ventral rami, it appears at the medial margin of the psoas major, descends over the pelvic brim anterior to the sacroiliac joint to join the first ventral sacral ramus¹. The sacral plexus is formed by the lumbosacral trunk, the first to third sacral ventral rami, and part of the fourth sacral ventral ramus (the remainder of which joins the coccygeal plexus¹).

The lumbosacral plexus as a whole is formed by the union of the anterior primary divisions of the lumbar, sacral, and coccygeal nerves. In about 50% of cases it

receives a branch from the twelfth thoracic nerve. Its components are distributed to the lower extremity in a manner homologous and similar to the distribution of the parts of the brachial plexus to the upper limb². Partly for convenience of description and partly because of the differences in position and course of some of the nerves arising from it, the lumbosacral plexus is subdivided into four parts: the lumbar, sacral, pudendal, and coccygeal plexuses².

Materials & Methods

Variation in the formation of the femoral nerve, a branch of lumbar plexus, was found during routine dissection of a 60 years old male cadaver in the Department of Anatomy, Calcutta National Medical College of Kolkata, in the year 2011. Posterior abdominal wall was dissected minutely to find out different branches of lumbar plexus and the lumbosacral trunk; the psoas major muscle was cut for that purpose. Roots and branches of the lumbar plexus and the lumbosacral trunk were painted. Relevant photographs were taken.

Observation

On the right side of the posterior abdominal wall, femoral nerve was formed by the dorsal branches of the ventral rami of L2, L3, and L4 spinal nerves as usual. An extra nerve branched out from the lumbosacral trunk, crossed both ventral and dorsal branches of L4 spinal nerve superficially to join with the femoral nerve [Photograph 1]. After tracing the fibres of this additional branch, it was found that the fibres were derived from the ventral ramus of the L5 spinal nerve. So, in this case the femoral nerve received additional fibres from the L5 root via the lumbosacral trunk.

Other branches of lumbar plexus on the right side were formed according to normal anatomy. No variation was found among the different branches of lumbar plexus on the left side.

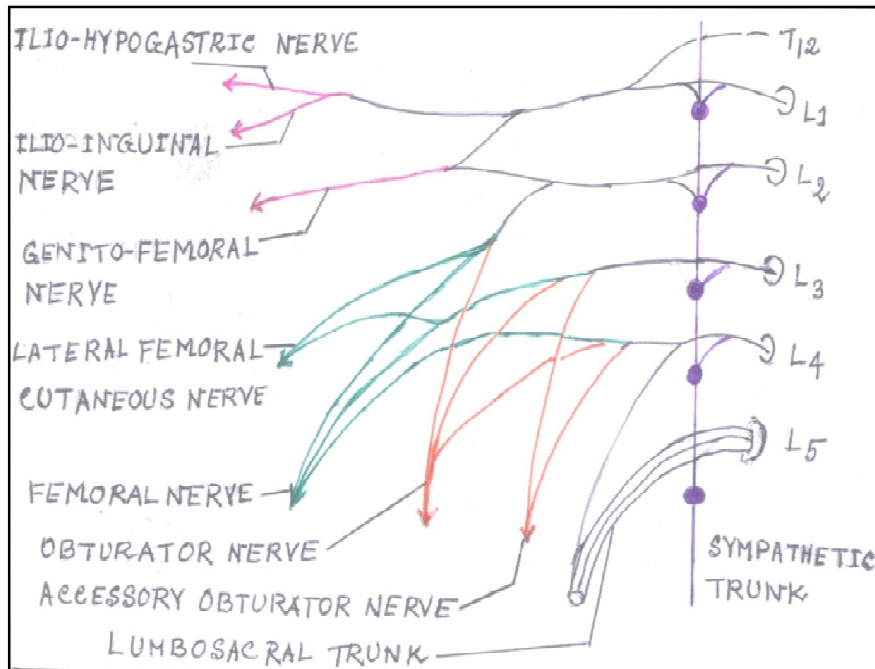
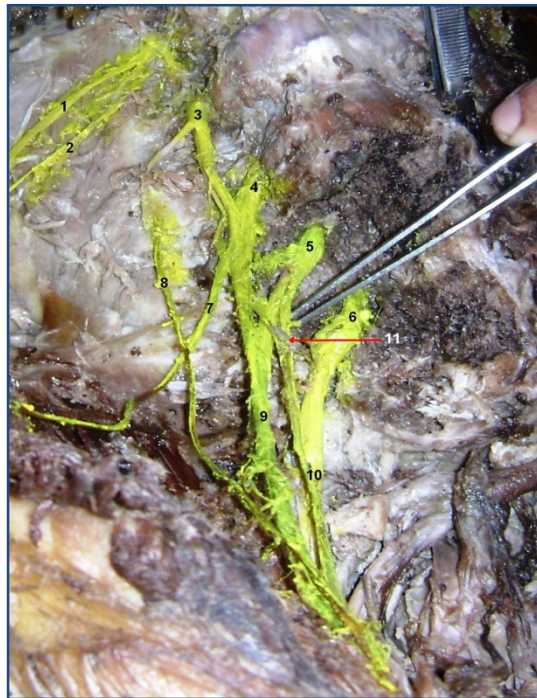


Figure 1 : Diagram showing the Lumbar Plexus.



Photograph 1: Lumbar Plexus with one additional branch from the lumbosacral trunk joining the femoral nerve.

Index –

- | | |
|---------------------------------------------------------------------------------|------------------------------------------|
| 1- Iliohypogastric nerve | 6 - ventral ramus of the L5 spinal nerve |
| 2- Ilioinguinal nerve | 7- Lateral femoral cutaneous nerve |
| 3 – Ventral ramus of the L2 spinal nerve | 8 - Genitofemoral nerve |
| 4 – Ventral ramus of the L 3 spinal nerve | 9 - Femoral nerve |
| 5- Ventral ramus of the L4 spinal nerve | 10- Lumbosacral trunk |
| 11- One additional branch from the lumbosacral trunk joining the femoral nerve. | |

Discussion

In its usual form, the ventral rami of the first three lumbar nerves are entirely distributed to the lumbar plexus. The ventral ramus of the fourth lumbar nerve is divided between the lumbar and sacral plexuses, hence it is called the furcal (meaning forked) nerve. The name furcal is also applied to any nerve or nerves that enter into the formation of both the

lumbar and sacral plexuses. The proportion of the fourth lumbar contributing to the sacral plexus, however, is variable ². Furcal nerves usually arise from L4, in a "high form" from L3, in a "low form" from L4 and L5 or from L5 alone. The femoral nerve usually is derived from L1, L2, L3, and L4 roots, in a "high form" from T12, L1, L2, L3 and L4 roots or in a "low form" from L1, L2, L3, L4, and L5 roots ².

In the present case the femoral nerve had a contribution from the L5 (ventral ramus of the 5th lumbar spinal nerve) through the lumbosacral trunk (like the low form of the lumbar plexus). The lumbosacral plexus is frequently asymmetric bilaterally² and it has been revealed from the present case also. Multiple variations of the nerves arising from the lumbar plexus were found on the right side of a 35-year old female cadaver by Uzman et al in 2006³ where the femoral nerve was formed by the union of the posterior divisions of L2-L4 spinal nerves and 5.2 cm after its formation, it was receiving a slender branch from the lateral femoral cutaneous nerve (LFCN)³ which is normally a branch of the lumbar plexus. But in one study the origin of the lateral femoral cutaneous nerve was from the femoral nerve in four lumbar plexuses⁴. These cases had variations of the femoral nerve, but the present case was unique in its finding where the femoral nerve received an additional twig from the ventral ramus of the L5 root through the lumbosacral trunk.

Clinical Anatomy: The unusual branches of the lumbar plexus and lumbosacral trunk may be injured during certain surgical procedures, particularly in the lower abdominal region (appendectomy, inguinal hernia repair, iliac crest bone graft harvesting and gynecologic procedures through transverse incision)³. The separation of the psoas muscle during retroperitoneal endoscopic surgery, injury of the lumbar plexus is a potential risk³. Femoral nerve is used for nerve block in several surgeries and is vulnerable to compression in tight ilio-psoas compartment⁴.

Conclusion

The knowledge of origin and variations of femoral nerve is important for anatomists, anesthetists and surgeons to prevent iatrogenic femoral nerve palsy⁴. This case will contribute to enhance our knowledge in Neuroanatomy.

Acknowledgement: We are grateful to Professor Rita Roy, Professor Sibani Mazumdar and other members of the Department of Anatomy, Calcutta National Medical College, Kolkata, West Bengal, India, for their kind co-operation to complete this case report.

References

1. Standring S, Gatzoulis MA, Borley NR, Collins P, Wigley C, Healy JC, Khan N, Moore LA (editors) (2008). In: Gray's Anatomy, The Anatomical Basis of Clinical Practice. Posterior Abdominal Wall and Retroperitoneum; True Pelvis, Pelvic Floor and Perineum. 40th Edition. Spain, Churchill Livingstone Elsevier. 1078-1080, 1091-1092.
2. Bergman RA, Afifi AK, Miyauchi R. Illustrated Encyclopedia of Human Anatomic Variations. Opus III: Nervous System: Nervous System Listing by Regions : Plexuses and Nerves. Downloaded from: <http://www.anatomyatlases.org/AnatomicVariants/NervousSystem/Regions/Regions.shtml> (accessed in March 2013).

3. Uzmanseel DD, Aktekin M, Kara A (2006). Case Report: Multiple variations of the nerves arising from the lumbar plexus. *Neuroanatomy*. 5: 37–39
4. Astik BR, Urvi H Dave UR (July 2011). Anatomical Variations in Formation and Branching Pattern of the Femoral Nerve in Iliac Fossa: A Study in 64 Human Lumbar Plexuses. *People's Journal of Scientific Research* 14 Vol. 4(2):14 -19.

Date of submission: 18 February 2013

Date of Provisional acceptance: 12 March 2013

Date of Final acceptance: 28 April 2013

Date of Publication: 03 June 2013

Source of Support: Nil ; Conflict of Interest: Nil