

## Case Report:

# Variations in the arterial supply of the thyroid gland in an Indian Male Cadaver

**Dr Satabdi Sarkar, Dr Banani Kundu, Dr soumyedhik Dey, Dr Pallab Kumar Saha ,  
Dr Rudradev Meur, Dr Anirban Sadhu,**

Corresponding author : Dr Satabdi Sarkar

Name of the Institute/college: R.G.Kar Medical College, Kolkata, India

---

## ABSTRACT:

**Introduction:** The knowledge regarding the variations of vascular supply of thyroid gland was very much important for thyroid surgeries.

**Methodology:** The object of present study to report an unusual variation in the origin of superior thyroid artery and high up division of inferior thyroid artery during routine dissection of an adult male embalmed cadaver .

**Observation & Result:** The left superior thyroid artery took origin from the left common carotid artery and supplied the superior aspect of left lobe of the thyroid gland. The relationship of the left superior thyroid artery with the left external laryngeal nerve was normal . The inferior thyroid artery showed high up division in an unusual pattern. In right side the origin and distribution of both arteries were normal .

**Conclusion:** Careful observation as well as knowledge of such arterial variations of the thyroid gland was very necessary for surgeons in order to avoid damage to vital structures in neck .

**Key words:** common carotid artery, superior thyroid artery, inferior thyroid artery

---

## INTRODUCTION

Surgeries of the thyroid gland demand a proper knowledge about the gross anatomy of the neck region and the anatomical variations of the structures located within it .<sup>1</sup>Normally the superior thyroid artery took its origin from the anterior surface of external carotid artery just below the greater cornu of hyoid bone and descended anterolateral to the external branch of the superior laryngeal nerve to reach the superior pole of the thyroid gland<sup>2</sup>. The ELN crossed the STA from lateral to medial, either above or below the superior pole of the thyroid. The common carotid artery usually did not provide any branch in the neck. The inferior thyroid artery take its origin from the thyrocervical trunk

and loops upward then turns medially just below the transverse process of c<sub>6</sub> and descends to the lower border of thyroid gland. Near the base of thyroid gland it divides into two branches to supply the inferior and posterior surfaces of the thyroid gland. The relationship of Recurrent laryngeal nerve and inferior thyroid artery is quite variable. On left side it lies between the branches of the inferior thyroid artery in major cases. In decreasing order of frequency, it is positioned posterior and anterior to the inferior thyroid artery. In greater than 60% case the relationship of one side do not match with the opposite side<sup>3</sup>.

The role of superior thyroid artery in head and neck region surgeries is great as it frequently

uses as a recipient vessel in microvascular free tissue grafting for specific embolization of thyroid and other head and neck tumors. It also acts as a guide for identifying the superior laryngeal nerve in thyroid surgery as it supplies the tensor of the vocal cord.

Consequently, it is important to have a clear knowledge regarding the branches and variations of this artery. Variations in the thyroid vasculature are frequently documented in classical anatomical, surgical and radiological textbooks. Most studies showed the anatomic variation of the inferior thyroid artery and the recurrent laryngeal nerve, and few have demonstrated variations of the superior thyroid artery (STA) and the external laryngeal nerve (ELN). Past studies have reported the incidence of origin of the superior thyroid artery from the common carotid artery in 5-45% cases<sup>4</sup>.

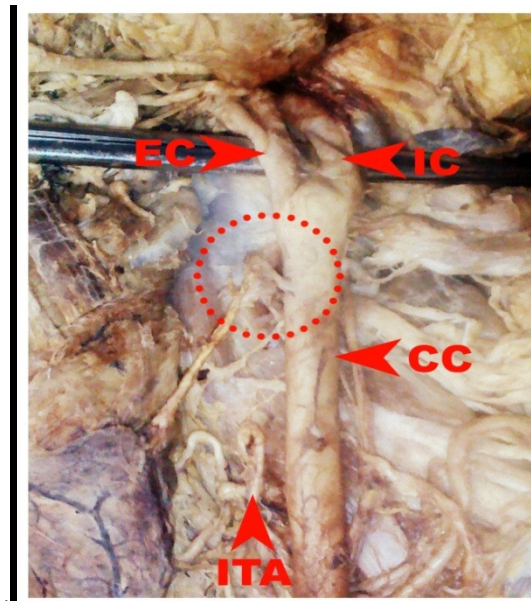
#### MATERIALS AND METHOD

We found the developmental variation in a 62 years old embalmed Indian male cadaver during routine dissection in anatomy department of R.G.Kar Medical College, Kolkata. No history of vascular surgical intervention was obtained. After proper clearing of important neck structures we found the developmental variation and compared it with the opposite side. A clear photo of that variation was taken.

#### OBSERVATION AND RESULT

During routine dissection in a 62 year old Indian male cadaver we found an unusual unilateral variation regarding the origin of superior thyroid artery and high up division of inferior thyroid artery. The superior thyroid artery of left side took its origin from anteromedial side of common carotid artery instead of external carotid

artery. The course of superior thyroid artery and its relation with external laryngeal nerve was normal. The inferior thyroid artery took its origin from the thyrocervical trunk, ascended upward up to fifth cervical vertebrae instead of sixth cervical vertebrae. Then it formed a loop in its course and underwent division near the upper pole of thyroid gland which usually occur near the lower pole. Though the bifurcation of inferior thyroid artery took place at higher level than usual cases. The recurrent laryngeal nerve lied in between the two divisions of inferior thyroid artery which supplied the posterior and inferior surface of thyroid gland. The origin, course and relation with laryngeal nerve of both thyroid arteries was normal on opposite side.



**Picture:** origin of superior thyroid artery and high up division of inferior thyroid artery

EC: external carotid artery      IC: internal carotid artery  
CC: common carotid artery      ITA: inferior thyroid artery

Red dotted circle shows the origin of superior thyroid artery

### DISCUSSION

Variations of origin of superior thyroid artery was presented by many authors.<sup>5</sup>

Our study was unique in prospect of origin of superior thyroid artery from common carotid artery and the course of inferior thyroid artery.

Teresa Va'zquez et al described the Variations in the origin of STA and SLA from the carotid arterial tree and classify the origins of these arteries.<sup>6</sup> Vandana Mehta et al reported a case where the right superior thyroid artery was absent and the left superior thyroid artery took origin from the left common carotid artery and supplied the superior aspect of both the left and right lobes of the thyroid gland.<sup>7</sup>

Common carotid artery develop from the ventral part of third aortic arch and External carotid artery sprouts cranially as a new vessel from the third aortic arch. Part of Precostal anastomosis of the intersegmental arteries of cervical region persist as thyrocervical trunk. An embryological

explanation for the variation in the present case could be the persistence or reappearance of vascular system in relation to the derivative of third aortic arch. These persisting or reappeared channels supplement or substitute the regular arteries, thereby securing blood supply to that side of thyroid gland, which had variant arterial supply.

### CONCLUSION

These arterial variations related to the thyroid gland is of immense importance in formulating planned surgical approaches to the thyroid gland and in alerting the surgeons to avoid inadvertent injuries to the vital anatomical structures in this area. Additionally, a detailed knowledge of these explicit arterial variations is extremely helpful while carrying out procedures like carotid angiographies, neck dissections and thyroid resections. Knowledge of such variations of superior thyroid and inferior thyroid arteries has immense importance in academic and clinical arena.

### REFERENCES

1. Vázquez T, Cobiella R, Marañillo E, Valderrama F J, McHanwell S, Parkin I, Sañudo JR. 2009. Anatomical variations of the superior thyroid and superior laryngeal arteries. *Head Neck* 31: 1078-85.
2. Thwine S, Soe M, Myint M, Than M, Lwin S. 2010. Variations of the origin and branches of the External Carotid artery in a human cadaver. *Singapore Med J* 51: e40-2.
3. Campos BA, Henriques PR. Relationship between the recurrent laryngeal nerve and the inferior thyroid artery: a study in corpses. *Rev Hosp Clin Fac Med Sao Paulo*. Nov-Dec 2000; 55(6):195-200. [[Medline](#)].
4. Smith SD, Benton RS. A rare origin of superior thyroid artery. *Acta Anat* 1978;101:91-3
5. Lucev N, Bobinac D, Maric I, Drescik I. Variations of the great arteries in the carotid triangle. *Otolaryngol Head Neck Surg* 2000;122:590-591.

6. Teresa Va´zquez 1, Rosana Cobiella 1, Eva Maranillo 1, Francisco Jose Valderrama 1, Stephen McHanwell 2, Ian Parkin 3, Jose Ramon San˜udo 1, ANATOMICAL VARIATIONS OF THE SUPERIOR THYROID AND SUPERIOR LARYNGEAL ARTERIES, 1 April 2009 in Wiley InterScience (www.interscience.wiley.com). DOI: 10.1002/hed.2107
7. Vandana Mehta1, Rajesh.K.Suri 2, Jyoti Arora 3, Gayatri Rath4, Srijit Das5 Anomalous Superior Thyroid Artery, Kathmandu Univ Med J 2010; 9(32): 426-428

Date of submission: 29 March 2014

Date of Publication: 09 June 2014

Source of support: Nil, Conflict of interest: Nil