

## Case Report :

# Bowel metastasis from carcinoma cervix: A rare case report

\*Dr. Joshi Sneha R, Dr. Tekwani Deepa T, Dr. Mangala Nagre

Department Of Pathology, MIMER Medical College , Talegaon Dabhade, Pune , Maharashtra

\*Corresponding author: E-mail: sneharjoshi53@gmail.com

### ABSTRACT:

Bowel Metastasis from Carcinoma Cervix is extremely rare. We had 50 years old female patient who presented with sub acute intestinal obstruction in July 2005. She underwent Laparotomy with clinical diagnosis of ileo-caecal tuberculosis. Resection of adhered bowel consisting of part of terminal ileum, ascending colon and ileo-caecal junction was done with ileocolonic anastomosis. Ileo-caecal tuberculosis or any other primary bowel pathology was not found. Serosa at various levels of ileum, colon showed metastasis of moderately differentiated keratinising squamous cell carcinoma resembling that of cervix. After deliberate and intensive enquiry, it was found that patient had undergone Wertheim's hysterectomy for carcinoma cervix in February 2005 confirming the diagnosis of serosal metastasis of carcinoma cervix. Considering the rarity of bowel metastasis from carcinoma cervix and retrograde route of transmission, this case is presented.

---

### INTRODUCTION

Metastatic lesions in the bowel are uncommon and mostly occur as a part of generalized carcinomatosis.<sup>(1,2,3)</sup> The clinical picture of partial obstruction of bowel is most frequent in metastatic bowel wall lesions.<sup>(1,2)</sup> We report below such a case of bowel metastasis from carcinoma cervix presenting as subacute intestinal obstruction.

### CASE REPORT

50 Years old female patient was admitted in Talegaon General Hospital in June 2006 with pain in abdomen, vomiting and intermittent fever since 2-3 months. Clinical diagnosis of ileo-caecal tuberculosis was suggested. Patient had anaemia (Haemoglobin 8.7 gm%). X-ray, USG, CT scan abdomen revealed a large heterogeneous mass in right iliac fossa likely from bowel inflammatory in nature. Laparotomy was done and adhered bowel loops with thick mesentery were resected and ileocolonic anastomosis was done.

### GROSS EXAMINATION

The specimen received in pathology was adhered mass of ileal loops with thickened ileo-caecal junction. Mesentery showed whitish spherical nodule. Intestinal wall showed marked whitish thickening from outside-serosa to submucosa. Mucosa was normal at all levels (Fig.1).

### MICROSCOPY EXAMINATION

Sections from ileum showed deposits of grade II squamous cell carcinoma in serosa, muscle coat and up to submucosa at some places (Fig. 2,3). Mucosa was normal in all places. Mesenteric masses also showed deposits of

grade II squamous cell carcinoma. No evidence of tuberculosis was seen. Considering gross and microscopy the diagnosis of metastasis of grade II squamous cell carcinoma in bowel was given.

In this case after deliberate and intensive enquiry it was found out that patient had undergone Wertheim's hysterectomy for carcinoma cervix in Feb. 2005- confirming the diagnosis of bowel metastasis from carcinoma cervix.

## DISCUSSION

Secondary involvement of bowel in malignant disease is rare.<sup>(1,2,3,4)</sup> The metastasis may come from carcinoma cervix<sup>(1,2)</sup>, melanoma<sup>(1,2,4)</sup>, Other parts of GIT<sup>(4)</sup>, Oesophagus<sup>(5)</sup>, Lung<sup>(4)</sup>, breast<sup>(6)</sup>. The present case showed metastasis of grade II squamous cell carcinoma of cervix in the bowel. Hendrinson quoted ileal involvement in 3.2% of untreated and 1.2% treated of fatal cases of carcinoma cervix.<sup>(3)</sup> Decastro et al<sup>(1)</sup> had eight cases of bowel metastasis from carcinoma cervix out total twenty-six cases of metastatic tumors of small bowel In series of Farmer<sup>(2)</sup> five cases of bowel metastasis from Carcinoma Cervix were noted out of fourteen metastatic bowel cases Mathur<sup>(3)</sup> had single case report of secondary of Carcinoma Cervix in bowel. The routes of metastasis to ileum depend upon primary site. When lesion is in abdomen or pelvis routes are<sup>(3)</sup> as Retrograde lymphatic spread following initial blockade of para-aortic or mediastinal + lymph nodes,<sup>(1)</sup> Peritoneal seedling, Direct extension, Haematogenous.

In the present case retrograde route is likely as Absence of peritoneal seedlings, Absence of direct extension, Presence of lymphatic emboli and Mesenteric masses as completely replaced lymph nodes.

The lesions in the present case are in the form of mesenteric spherical masses and thickened bowel wall due to involvement of Serosa to submucosa by tumor growth. In series of Farmer<sup>(2)</sup> in addition to lesions described in our case, intramural masses with ulceration and bulky polypoid masses in bower lumen are also described. Mathur<sup>(3)</sup> described solitary ileal stricture due to metastasis. Clinical presentation in the present case is partial obstruction, which is the most frequent clinical picture in metastatic bowel.<sup>(1,2,4)</sup> Perforation and hemorrhage were also noted in cases from Cleveland<sup>(2)</sup> Palliative Laparotomy to relive the obstruction is the treatment of choice.

Fig. 1: Gross specimen of ileum with enlarged mesenteric lymph nodes.

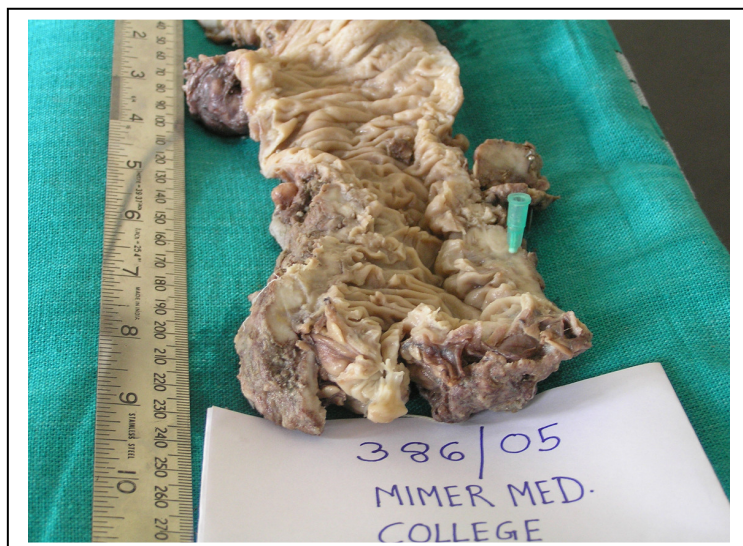

Fig. 2: Photomicrograph of ileum showing normal mucosa and growth (H&E 10X).

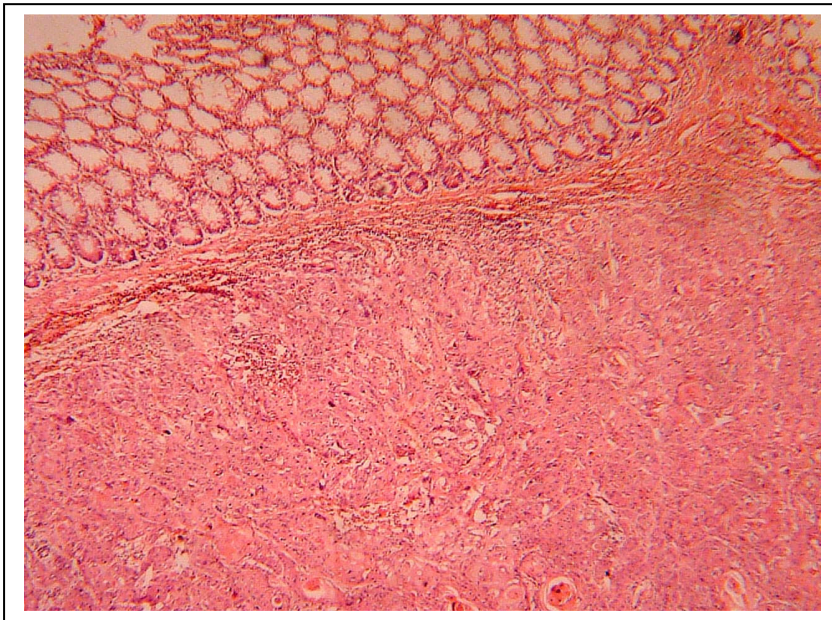
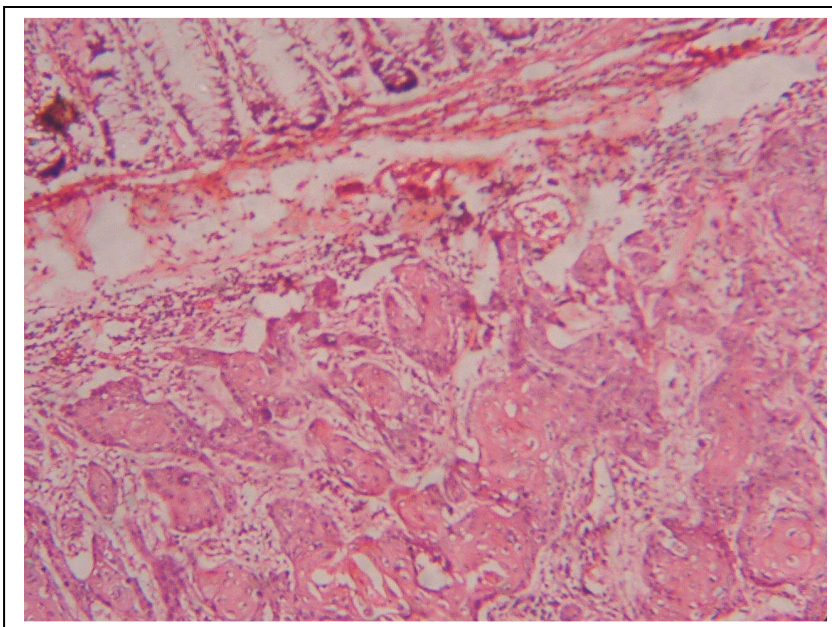


Fig. 3: Photomicrograph of ileum showing normal mucosa and growth (H&E 40X).



**REFERENCES:**

1. Decastro C. A., Dockerty, M.B. and Mayo, C.W. Metastatic tumors of small intestine. *Surg Gynecol and obstet.* 105: 159-165, 1957.
2. Farmer, R.6. and Hawk, W.A. Metastatic tumor of small bowel *Gastroenterology*, 47: 496-504, 1964.

3.Mathur S.K; Pandya GP Solitary metastatic malignant stricture of the ileum: a rare cause of small bowel obstruction C A case reports. Journal of postgraduate Medicine 30-3: 186-188, 1984:

4.Agustin A Burgos., Miguel Martinez; Bemard M Jaffe. Tumors of small intestine in “Maingot’s Abdominal Operations” Editors: Michael J Zinner, Seymour I Schwartz, Harold Ellis. 10<sup>th</sup> edition Vol. 2. Appleton and Lange, Stamford Connecticut, 1997, pp- 1183.

5.Neve R.S. Gureshi S.S, Mistry Rajesh C. Ileal Metastasis from Oesophageal carcinoma causing intestinal Obstruction. Journal of Postgraduate Medicine 51:74-75. 2005.

Date of submission: 07 June 2013

Date of Provisional acceptance: 19 June 2013

Date of Final acceptance: 27 July 2013

Date of Publication: 04 September 2013

Source of support: Nil

Conflict of Interest: Nil